

THE USE OF COBLATION IN VOLUMETRIC TUMOR REDUCTION OF THE RHINOPHARYNGEAL NEOPLASM FOR AVIATORS

Cristian Dragos STEFANESCU*, Viorel ZAINEA**, Mura Hainarosie**,
Razvan HAINAROSIE**

*"Gen. Dr. Aviator Victor Anastasiu" National Institute of Aeronautical and Space Medicine,
**„Carol Davila" University of Medicine and Pharmacy, Bucharest

Abstract: *The aim of this paper is to present technic and technological aspects related to coblation surgery on the malignant tumors of the nasopharynx. The methodology of this paper is to investigate pre- and post-operative aspects of the neoplasms of the nasopharynx which underwent volumetric reduction using coblation surgery. The conclusions emphasize the utility of coblation technology associated with endoscopy and Narrow Band Imaging for the surgical approach of malignant tumors of the nasopharynx in aviators. The efficient screening, diagnosis and treatment of nasopharynxneoplasms in the case of aviators will lead also to a reduction of the costs associated with the aggravation of disorders.*

Key words: *nasopharynx , coblation, neoplasm*

INTRODUCTION

The treatment for nasopharyngeal malignant tumors is multimodal: radiotherapy, chemotherapy and surgery. The last one plays an important role in the diagnostic stage allowing the surgeon to approach the tumor, to harvest a biopsy and in the therapeutic stage contributing to improvement of symptoms such as nasal obstruction, otitis media with effusion. The endoscopic approach of the nasopharynx can be done in two ways: trans-nasal with 0° telescopes and tras-oral with angled telescopes (30°, 45°, 70°). In some cases we use combined endoscopic approach, both trans-nasal and trans-oral, for a better evaluation of the whole nasopharynx (especially the key zones like Rosenmuller fossa, torus tubaris).

MATERIAL AND METHODS

The paper presents practical aspects of using coblation surgery on rhinopharyngeal neoplasms and discusses the exposure of the nasopharyngeal tumors through endoscopic approach of the nasopharynx and the use of coblation surgery in the management of rhinopharyngeal neoplasm.

When alarge tumor is approached it is not enough to take a small biopsy, it is important to reduce the volume of the tumor for a better response to radiotherapy and chemotherapy and for easing the obstruction symptoms of the patient[1].

The reduction of the tumor can be realized with coblation. This technique is using plasma based radiofrequency instruments that are able to remove the tissue [2]. The coblation technique works in three different manner: ablation of the tissue (removing an entire volume of tissue/ tumor during surgery), volume reduction of the tissue (decreasing the volume of the tissue/ tumor using thermal energy during surgery) and hemostasis (coagulation of the vessels or cauterizing the tissue in order to stop the bleeding).

The coblation device uses frequencies between 100 and 500 KHz to cut the tissue with minimal necrosis of the surrounding anatomic structures.

The device works in saline environment with (high tension electrical excitation with cutting of the tissue) or without (low tension electrical excitation with heating of the tissue) plasma production.

The Use of Coblation in Volumetric Tumor Reduction of the Rhinopharyngeal Neoplasm for Aviators

The saline solution is conducting the electrical power generated between the active electrodes of the coblation probe and the neutral electrode and the chemical corrosion of plasma produced in the saline environment is cutting the tissue at low temperature with minimal effects on the surrounding structures.

Hemostasis is obtained without plasma production and the coagulation takes place at lower temperatures compared with conventional electrocautery.

The coagulation is achieved through contraction of the elastin fibers of the vessel and reduction of the vessel's diameter and through protein coagulation in the plasma.

Nasopharyngeal coblation surgical approach was made taking into account the surgical risk factors of the anatomic region and the advantages of this technology that is based on a low thermal effect, but strongly melting power. These properties of coblation decrease the surgical risk of vulnerable anatomical structures encountered in the nasopharynx [3].

On the nasopharyngeal upper side wall are high surgical risk landmarks of endoscopic anatomy, such as the internal carotid artery (that corresponds to Rossenmuller fossa), torus tubaris and the pharyngeal orifice of the Eustachian tube.

Coblation and endoscopic techniques allow a good approach of the nasopharyngeal tumor with lower injury risks for the key areas of the nasopharynx.

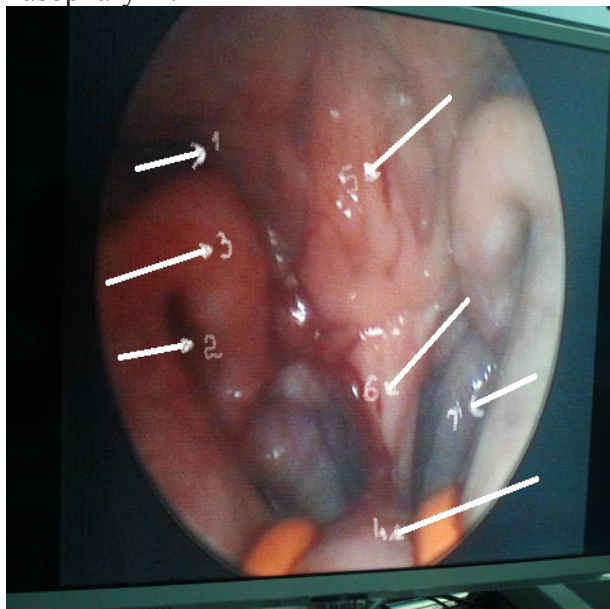


Fig. 1 - Endoscopic transoral nasopharyngeal view with 70° endoscope - 1. Rossenmuller fossa; 2 - pharyngeal orifice of the Eustachian tube; 3 - torus tubaris; 4 - soft palate; 5- Posterior wall of the rhino pharynx; 6 - nasal septum (vomer); 7 - inferior turbinate.

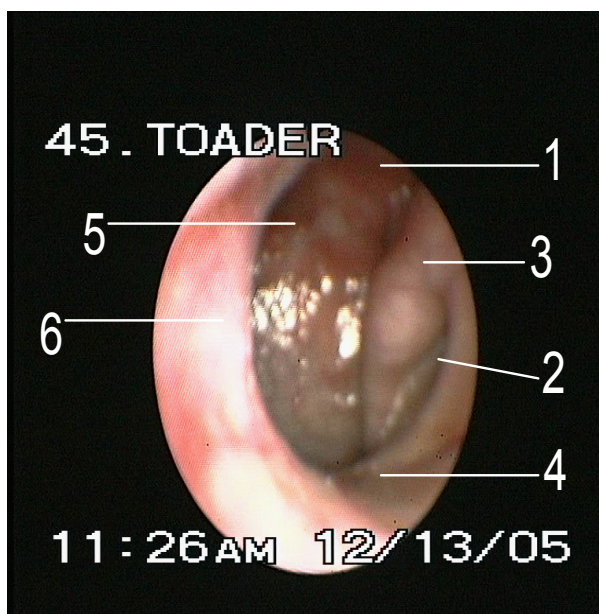


Fig. 2- Endoscopic trans nasal rhino pharyngeal image 0° endoscope: 1. Rossenmuller fossa; 2 - pharyngeal orifice of the Eustachian tube; 3 - torus tubaris; 4 - soft palate; 5- Posterior wall of the rhino pharynx; 6 - nasal septum

The mechanical ensemble used consists of: special retractor with support for the cheeks and tongue; 0°, 30°, 45° and 70° rigid endoscope; special forceps for the trans nasal and trans oral approach [2]. For the transoral approach of the nasopharynx, the soft palate is risen with two Nelaton probes offering a better view of the anatomic and endoscopic landmarks.

Fiberscope with NBI (Narrow Band Imaging) can be used for a better assessment of the vascularization of the tumor (tumoral neo-vessels)[4]. This is a new endoscopic technique that may improve the accuracy of diagnostic for the premalignant and malignant tumors of the nasopharynx using narrow-bandwidth filters in red-green-blue illumination. NBI allows the analysis of two aspects of the tissue examined: the vascular network and the architecture of the epithelium. In nasopharyngeal carcinoma the vascular network presents vascular proliferation (neo-vessels) and turgid blood vessels [5]. The evaluation of these two patterns offers data for the premalignant or malignant status of the tumor. Using this investigation during surgery, better assessment of the margins of resection can be made.

Obtaining tumor free resection borders is essential for a better outcome of the patient after radiotherapy and/or chemotherapy. There are new radiotherapy protocols, like IMRT (intensity modulated radiation therapy) that were proven to be more effective in treating the tumor and less harmful for the vicinity tissues [6].

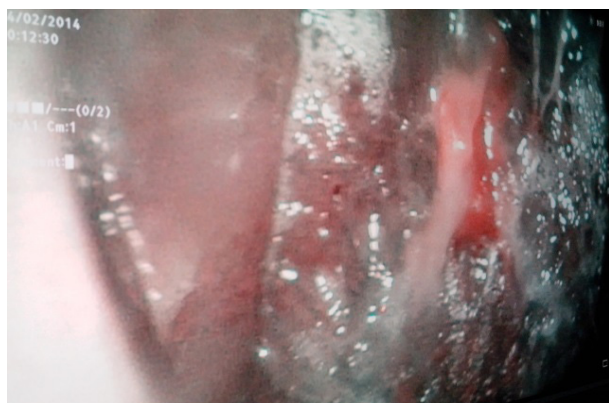
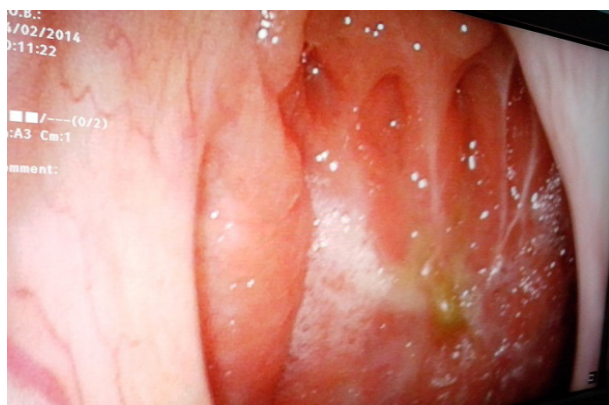

Fig. 3 – Fiberscope view of the nasopharynx

Fig. 4 – NBI view of the nasopharynx

The imagistic investigation is mandatory for surgery. Craniofacial CT or MRI with gadolinium provides the adequate information in terms of tumor localization and dimension, neighbor tissue invasion. The histopathological and/or immunohistochemistry examination of bioptic samples establish the definitive diagnosis and based on these results the patient continues with radiotherapy and chemotherapy as recommended by the oncologist.

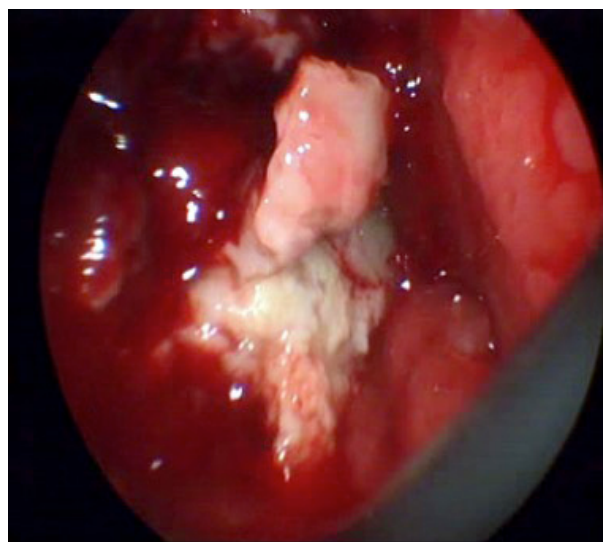


Fig. 5 – Nasopharyngeal tumor – intraoperative aspect

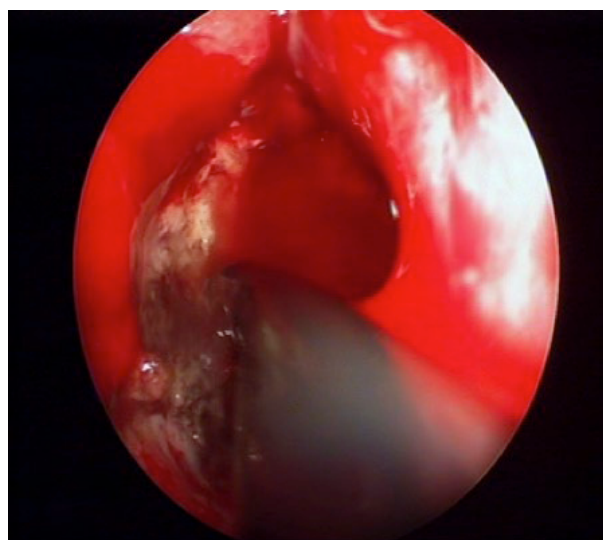


Fig. 6 – The use of coblation for nasopharyngeal tumors

Devices, surgical techniques and technologies used:

We used the specific device driver for nasopharyngeal endoscopic approach, the trans-oral and trans-nasal endoscopic techniques and PROcise®mAx Plasma Wand coblation probe. We also used several accessories and classic and endoscopic instruments.

CONCLUSIONS

The pathology of the nasopharynx became more and more accessible after the development of endoscopic techniques. Once the rhinopharynx became approachable a number of specific tools for proper access to this area were designed. Remarkable progress was made in the surgical technologies that can be used in the nasopharyngeal area. Coblation surgery is a safe and precise method and it can be used in the vicinity of considerably high risk surgical regions because of its decreased thermal effect to the surrounding tissues [3]. The association between coblation, endoscopy and NBI [4] is effective in obtaining tumor free resection borders and improving the response of the patient to radiotherapy and chemotherapy.

Coblation surgery have proved its' efficacy in volumetric tumor reduction of nasopharyngeal neoplasm and it improves the quality life for the patients due to delay of the complications and malfunction in the nasopharyngeal perimeter (impaired nasal breathing, altered permeability of the pharyngeal orifice of Eustachian tube, presence of descendent nasopharyngo-traheal suppurative complications).For the ENT aviationmedical expert, coblation surgery is an excellent method in the approach and management of intricate borderline cases.The efficient screening, diagnosis and treatment of nasopharynx neoplasms in the case of aviators will lead also to a reduction of the costs associated with the aggravation of disorders.

Acknowledgement:

This paper is partly supported by the Sectorial Operational Programme Human Resources Development (SOPHRD), financed by the European Social Fund and the Romanian Government under the contract number POSDRU 141531.

BIBLIOGRAPHY

- 1.Hsu Ning-i, Shen Ping-hung, Chao Siew-shuen, Ong Yew-kwang and Li Cho-shun En bloc resection concept for endoscopic endonasal nasopharyngectomy: surgical anatomy and outcome. Chinese Medical Journal 2014;127(16):2934-2939:10.3760/cma.j.issn.0366-6999.20133189
- 2.Peters G, McLaughlin K, Nuss DW. Treatment of nasopharyngeal papillomatosis with coblation: a case series.Int Forum Allergy Rhinol. 2011 Sep-Oct;1(5):405-8. doi: 10.1002/alr.20016. Epub 2011 Aug 16.
- 3.Chin D1, Snidvongs K, Sacks R, Harvey RJ. Collateral thermal injury during endoscopic skull base surgery from endonasal CO2 laser and coblation.J Laryngol Otol. 2013 Jul;127 Suppl 2:S29-32. doi: 10.1017/S0022215113000510. Epub 2013 Apr 10.
- 4.Torretta S, Gaffuri M, Cantarella G, Pignataro L.Narrow-band imaging in the diagnosis of vascular nasal lesions.Am J Otolaryngol. 2013 Jan-Feb;34(1):75-8. doi: 10.1016/j.amjoto.2012.08.011.
- 5.Ho CY, Chan KT, Chu PY.Comparison of narrow-band imaging and conventional nasopharyngoscopy for the screening of unaffected members of families with nasopharyngeal carcinoma.Eur Arch Otorhinolaryngol. 2013 Sep;270(9):2515-20. doi: 10.1007/s00405-013-2354-y. Epub 2013 Jan 23.
- 6.Zong J, Lin S, Lin J, Tang L, Chen B, Zhang M, Zhang Y, Xu L, Chen Y, Xiao Y, Fang Y, Pan J. Impact of intensity-modulated radiotherapy on nasopharyngeal carcinoma: Validation of the 7th edition AJCC staging system Oral Oncol. 2014 Nov 6. pii: S1368-8375(14)00307-8. doi: 10.1016/j.oraloncology.2014.10.012. [Epub ahead of print]